



DIAGNOSTIC TECHNIQUES

DEEP SKIN SCRAPING

CONTENTS

WHEN DO I DO IT? : 3.1

WHAT CAN I FIND? : 3.1

WHAT DO I NEED? : 3.1

TECHNIQUE IMAGES : 3.2

HOW DO I DO IT? : 3.3

TIP : 3.3

WHEN DO I DO IT?

- In cases of suspected demodicosis (non-inflammatory alopecia, comedones, pustules, crusts, inflammatory alopecia)

WHAT CAN I FIND?

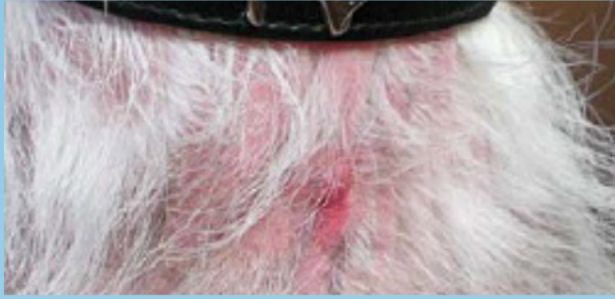- *Demodex* mites, including juvenile forms and eggs → more than one mite is diagnostic

WHAT DO I NEED?

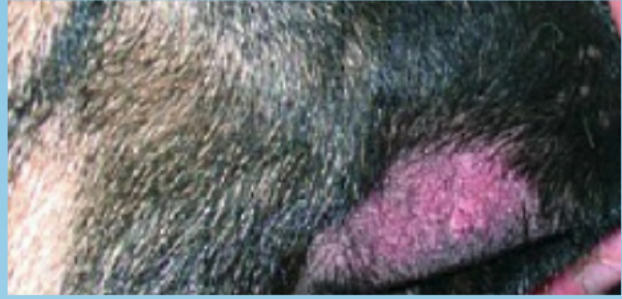
- Slides, cover slips, scalpel blade, mineral oil, microscope.

SKIN SCRAPING EQUIPMENT VIDEO: ExcellenceInDermatology.com → [Education Library](#) → [Videos](#)

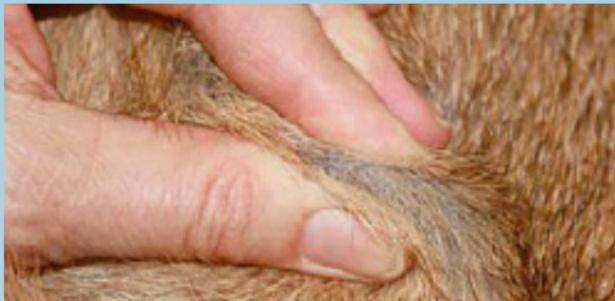TECHNIQUE IMAGES : DEEP SKIN SCRAPING



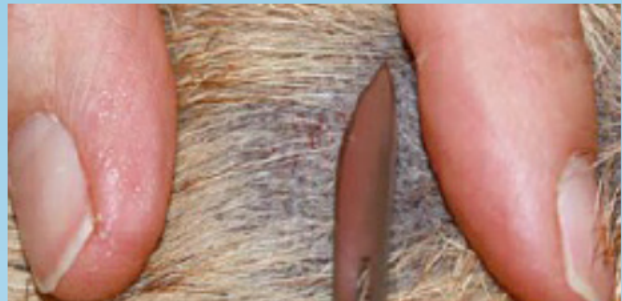Dog with demodicosis: inflammatory alopecia, hyperpigmentation (Courtesy: S. Bettenay)



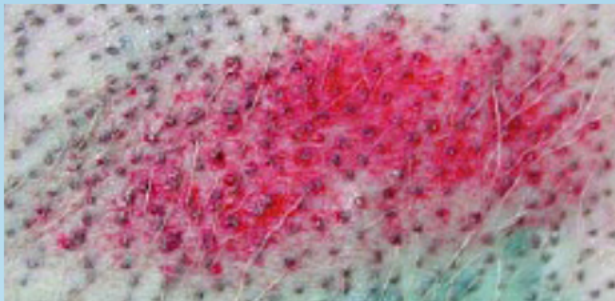
Focal alopecia due to demodicosis, puppy (Courtesy: F. Albanese, F. Leone)



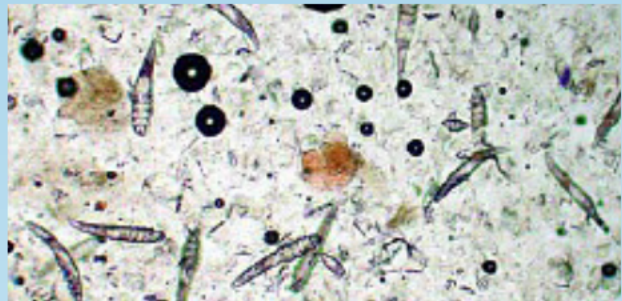
Squeeze skin prior to scraping (Courtesy: S. Bettenay)




Scrape until light capillary oozing is observed (Courtesy: S. Bettenay)



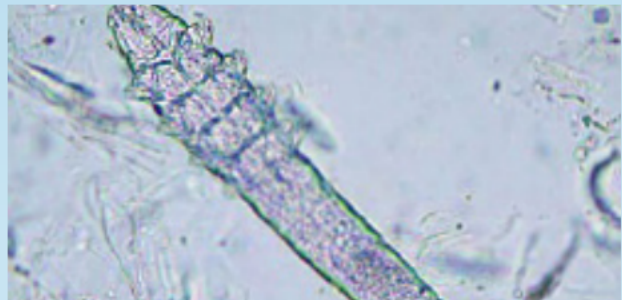
Excoriation after deep skin scraping (Courtesy: F. Albanese, F. Leone)



Demodex mites, adults and juvenile forms (Courtesy: F. Albanese, F. Leone)



Demodex mites, larvae and eggs (Courtesy: T. Nuttall)



Demodex canis (Courtesy: S. Bettenay)

HOW DO I DO IT?

- If necessary, clip 1cm² of the area you want to scrape to remove hairs
- Squeeze the skin prior to scraping to push the mites out from the depths of the hair follicles
- Scrape the skin in the direction of hair growth with a blade or spatula covered with mineral oil until capillary bleeding is observed
- Put the material on the slide
- Place a cover slip onto the sample and evaluate microscopically, using the 4x or 10x objective with the microscope condenser moved down.

SKIN SCRAPING PROCEDURE VIDEO: [ExcellenceInDermatology.com](#) → [Education Library](#) → [Videos](#)

TIP

- Feet and face are hard to scrape → Trichogram may give equivalent results if 1cm² of hairs is sampled.
- Some breeds (e.g. Shar Pei) are hard to scrape and a skin biopsy may be needed to make a diagnosis.